
Original Works

Experience of the Surgical Management of Extremely or Very Low-birth-weight Infants with Necrotizing Enterocolitis or Focal Intestinal Perforation

Eiichi Deguchi, Koji Higuchi, Shizu Tsukada
Shigehisa Fumino, Shigeru Ono and George Iwata

*Department of Pediatric Surgery, Japanese Red Cross Kyoto Daiichi Hospital**

Abstract: Background/Purpose: The purpose of this study was to report our surgical experience of the management of extremely (ELBW) or very low-birth-weight (VLBW) infants with intestinal perforation in the NICU of a municipal hospital.

Patients and Methods: The clinical records of 5 consecutive ELBW (<1,000 g) or VLBW (1,000-1,499 g) infants with intestinal perforation treated at the Japanese Red Cross Kyoto Daiichi Hospital between 2001 and 2009 were retrospectively reviewed.

Results: Four male and 1 female infants were diagnosed with intestinal perforation over the 9-year review period. Their mean birth weight was 834 g (534-1,042 g), and they had a mean gestational age of 26 weeks (23-29 weeks). Intestinal perforation was diagnosed between 2 and 27 days of life (median: 6 days). The overall survival rate was 4 of 5 cases. Primary peritoneal drainage (PPD) was performed as an emergent surgical procedure for 2 of 3 ELBW infants. Primary laparotomy with enterostomy was performed as the initial surgical intervention in 1 ELBW infant and 2 VLBW infants. The intestinal perforation sites were the colon in the 3 ELBW and the jejunum in both VLBW infants. Based on the operative findings, 4 of 5 infants were diagnosed with necrotizing enterocolitis, and 1 infant was diagnosed with focal intestinal perforation of the sigmoid colon. One ELBW infant who was treated with primary laparotomy did not survive, but the other 2 ELBW infants survived after PPD and subsequent laparotomy. Both VLBW infants survived after primary laparotomy combined with enterostomy.

Conclusions: In this series, PPD and subsequent laparotomy achieved better outcomes than initial laparotomy combined with enterostomy in ELBW infants with intestinal perforation.

Key Words: Neonatal surgery, Neonatal intestinal perforation, Primary peritoneal drainage.

Primary peritoneal drainage (PPD) is crucial for stabilizing infants with intestinal perforation. Recent reports have indicated that about one-third of infants with intestinal perforation who undergo PPD do not require further intervention¹⁻⁵⁾. However, subsequent laparotomy combined with enterostomy is essential for treating obstruction, sepsis, or uncontrolled fistula in some cases. The purpose of this study was to report our surgical experience of the management of extremely low-birth-weight (ELBW) or very low-birth-weight (VLBW) infants with intestinal perforation in the NICU of a municipal hospital.

MATERIALS AND METHODS

The records of 5 consecutive ELBW (<1000 g) or VLBW (1,000-1,499 g) infants with intestinal perforation treated at the Japanese Red Cross Kyoto Daiichi Hospital between 2001 and 2009 were reviewed. All infants underwent surgery. Birth and neonatal history were assessed for each case. A definitive diagnosis of intestinal perforation was made during surgery in all cases. Cases with complications secondary to obstruction, such as those involving neonates with intestinal atresia, Hirschsprung's disease, or meconium ileus were excluded. Clinical data, gestational age, sex, birth weight, neonatal asphyxia, enteral feeding before perforation, indomethacin administration, and the timing and clinical presentation of perforation were recorded.

RESULTS

Five infants (4 males and 1 female) with intestinal perforation were identified over the 9-year review period. Their mean birth weight was 834 ± 240 g (534-1,042 g), and their mean gestational age was 26 ± 2 weeks (23-29 weeks). Intestinal perforation was diagnosed between 2 and 27 days of life (median: 6 days). Pneumoperitoneum was diagnosed in 3 cases. Abdominal distension, the presence of free peritoneal fluid on an ultrasound scan, or bilious aspiration by paracentesis were used in the remaining 2 cases to make a clinical diagnosis of intestinal perforation. According to the typical radiologic criteria, only 1 infant was found to have necrotizing enterocolitis (NEC) at the time of perforation diagnosis. Three infants were diagnosed with patent ductus arteriosus and were treated with indomethacin, and 3 infants had been fed prior to perforation.

The overall survival was 4 of 5 cases. Primary peritoneal drainage (PPD) was performed as an emergent surgical procedure for 2 of the 3 ELBW infants. Primary laparotomy combined with enterostomy was performed as the initial surgery in 1 ELBW and both VLBW infants (Table 1). The initial surgery was either performed at 12 days of life (range: 2-28 days) or on the day of diagnosis or the day after diagnosis. The site of intestinal perforation was the colon in 3 ELBW infants and the jejunum in both VLBW infants. Based on the operative findings, 4 of 5 infants were diagnosed with NEC, and 1 infant (case 3) was diagnosed as having focal intestinal perforation (FIP) of the sigmoid colon.

The clinical courses and outcomes of the patients are summarized in Fig. 1. Primary peritoneal drainage was performed as an emergent surgical procedure for 2 ELBW infants. Both infants showed improvement and underwent subsequent laparotomy combined with enterostomy. In case 1, laparotomy and stoma were performed at 9 days after PPD. PPD was effective, and partial enteral feeding was indicated for case 3. However, recurrent sepsis occurred, and a CT scan revealed minimal leakage of the ingested dye. A second laparotomy was performed following this examination (at 28 days after the

Table 1. Outcome of 5 premature, low-birth-weight infants with intestinal perforation

Case	Gestational Age (weeks)	Birth weight (g)	Pneumoperiton-eum at diagnosis	Surgical intervention (date)	Perforation site	Outcome
1	23	534	present	PPD (21)	colon	survived
2	25	622	absent	Lap (5)	colon	succumbed
3	26	938	absent	PPD (28)	colon	survived
4	27	1038	present	Lap (6)	ileum	survived
5	29	1042	present	Lap (2)	ileum	survived

PPD: primary peritoneal drainage

Lap: primary laparotomy and stoma

initial surgery) and revealed penetration of the sigmoid colon. Both of these ELBW infants survived. The third ELBW infant received an emergent primary laparotomy, but succumbed to sepsis and disseminated intravascular coagulation at 9 days after the operation. Both VLBW infants survived after primary laparotomy combined with enterostomy. Stoma closure was performed 3-4 months after the stoma. The 4 surviving neonates were discharged from the hospital by 168 days (range: 133-224 days) of life.

CASE REPORTS

Case 1: A male 0.534-kg baby born by emergency caesarean section due to fetal distress at 23 weeks gestation was referred to our department on day 21 of life with marked abdominal distension. An abdominal X-ray revealed pneumoperitoneum. During peritoneal drainage, meconium contaminated ascites were drained, and the baby recovered from septic shock. A subsequent laparotomy revealed a perforation in the distal descending colon, and ileostomy was performed on the 9th day after peritoneal drainage. The baby recovered well, and the ileostomy was closed on day 97 of life.

Case 2: A male 0.622-kg baby born by emergency caesarean section due to fetal distress at 25 weeks gestation was referred to our department on day 5 of life with marked abdominal distension. An abdominal X-ray excluded pneumoperitoneum but showed increased ascites. During laparotomy, meconium contamination of the peritoneum was found together with a perforation in the distal descending colon. A loop stoma was formed in the terminal ileum after the perforation had been closed. The baby did not recover from septic shock and complicated disseminated intraluminal coagulation. An intra-abdominal hemorrhage occurred, which conservative treatment failed to control, and the baby succumbed to hemorrhagic shock on day 16 of life.

Case 3: A female 0.938-kg baby born by emergency caesarean section due to fetal distress at 26

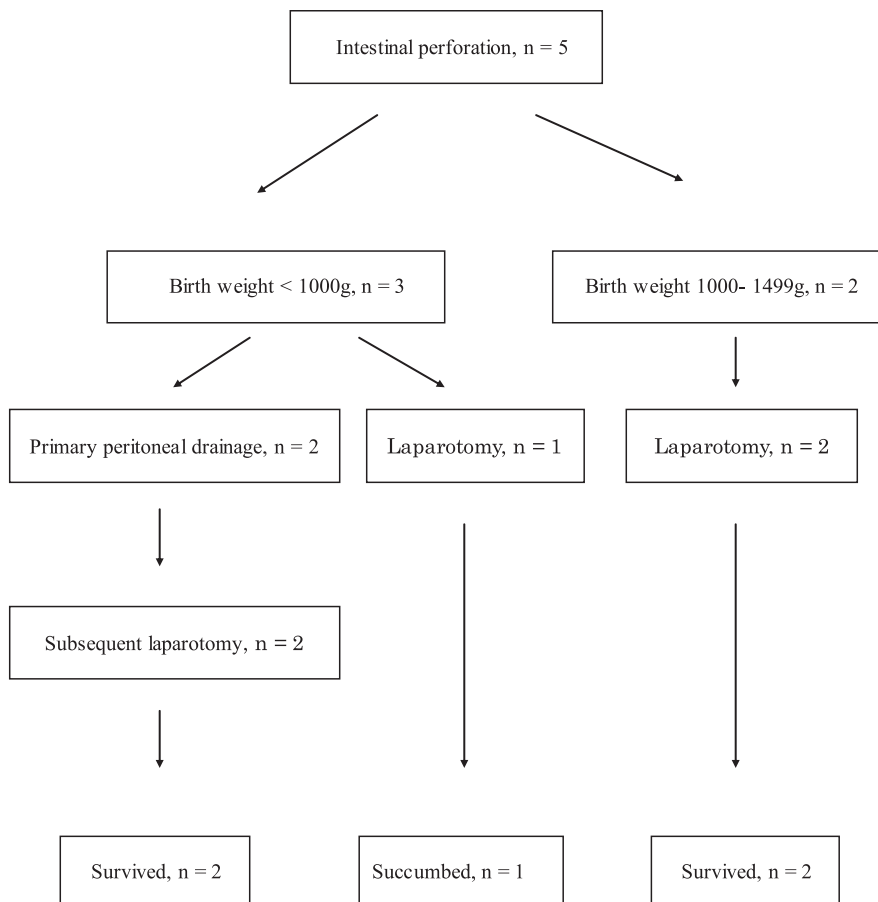


Fig. 1. Clinical course of 5 premature low-birth-weight infants with intestinal perforation

weeks gestation was referred to our department on day 27 of life with marked abdominal distension. An abdominal X-ray excluded pneumoperitoneum but showed increased ascites. During peritoneal drainage, meconium contaminated ascites were drained, and the baby recovered from septic shock. A subsequent laparotomy revealed retroperitoneal penetration of the sigmoid colon at 28 days after the peritoneal drainage. Partial resection of the sigmoid colon with colostomy was performed. The baby recovered well, and the colostomy was closed on day 211 of life.

Case 4: A male 1.038-kg baby born by emergency caesarean section due to fetal distress at 27 weeks gestation was referred to our department on day 6 of life with marked abdominal distension. An abdominal X-ray revealed pneumoperitoneum. During laparotomy, meconium contamination of the peritoneum was found together with a perforation in the terminal ileum. A loop ileostomy, in which the perforation site was located on the top of the loop, was performed, and ascites were drained. The baby recovered well, and the ileostomy was closed on day 80 of life.

Case 5: A male 1.042-kg baby born by emergency caesarean section due to fetal distress at 29 weeks gestation was referred to our department on day 2 of life with marked abdominal distension. An abdominal X-ray revealed pneumoperitoneum. During laparotomy, meconium contamination of the

peritoneum was found with a perforation in the terminal ileum. A loop ileostomy, in which the perforation site was located on the top of the loop, was performed, and ascites were drained. The baby recovered well, and the ileostomy was closed on day 72 of life.

DISCUSSION

Intestinal perforation may occur as a lethal complication of NEC or a focal intestinal punched-out lesion in VLBW or smaller infants. In 1977, Ein et al.⁶⁾ reported PPD as the definitive therapy for intestinal perforation in low-birth-weight infants. An ongoing discussion with regard to the merits of PPD and initial laparotomy combined with resection for managing intestinal perforation in VLBW or smaller infants has been initiated since this report. Twenty-six years since the study by Ein et al., Gollin et al.¹⁾ reported PPD as the optimal approach for the management of ELBW infants, with further reports insisting that surgical intervention is necessary for a small proportion (24%) of infants. In 2004, Michel et al.⁷⁾ reported peritoneal needle suction as a favorable strategy for managing VLBW infants with intestinal perforation. Thus, PPD is generally preferred by neonatologists. Survival after PPD is reported to be between 26 and 80%¹⁾²⁾⁸⁾.

Some investigators have expressed the opinion that ELBW infants are a distinct group that may respond better to PPD than larger infants⁴⁾⁵⁾⁷⁾. Other investigators have assessed outcomes in FIP as a separate entity from perforated NEC⁸⁻¹⁰⁾. Camberos et al.⁸⁾ reported a survival rate of 90% for infants with FIP managed with PPD. Rees et al.¹¹⁾ reported no significant difference in outcome between PPD and initial laparotomy in VLBW infants and recommended a timely “rescue” laparotomy for every PPD case.

PPD is performed to drain air, intestinal content, and infected fluid from the abdominal cavity. It also decompresses the distended abdomen and facilitates effective ventilation. The optimal treatment of an ischemic or necrotic intestine is surgical removal. In this study, we demonstrated a better outcome of PPD and subsequent laparotomy compared with initial laparotomy combined with enterostomy in ELBW infants with intestinal perforation. Although Camberos et al. reported similar mortality rates for initial laparotomy and PPD, they also reported a higher mortality rate for ELBW (30%) than for VLBW (13%) infants.

We recommend PPD for ELBW infants with intestinal perforation, as it is one of the best methods for stabilizing severely ill infants, thus allowing for subsequent definitive surgery. From our experience with ELBW infants with intestinal perforation, we recommend selecting a much gentler approach for treating ELBW infants than the logically ideal surgery. In our opinion, PPD should not be regarded as an alternative to laparotomy in infants with apparent panperitonitis caused by intestinal perforation, although it does aid the resuscitation of infants with severe conditions.

REFERENCES

- 1) Gollin G, Abarbanell A, Baerg JE. Peritoneal drainage as definitive management of intestinal perforation in extremely low-birth-weight infants. *J Pediatr Surg* 2003; 38: 1814-1817.
- 2) Goyal A, Manalang LR, Donnell SC, Lloyd DA. Primary peritoneal drainage in necrotising enterocolitis: an 18-year experience. *Pediatr Surg Int* 2006; 22: 449-152.
- 3) Alexander F, Smith A. Mortality in micro-premature infants with necrotizing enterocolitis treated by

- primary laparotomy is independent of gestational age and birth weight. *Pediatr Surg Int* 2008; 24: 415-419.
- 4) Holland AJ, Shun A, Martin HC, Cooke-Yarborough C, Holland J. Small bowel perforation in the premature neonate: congenital or acquired? *Pediatr Surg Int* 2003; 19: 489-494.
 - 5) Kubota A, Yamanaka H, Okuyama H, Shiraishi J, Kawahara H, Hasegawa T, Ueno T, Kitajima H, Kuwae Y, Nakayama M. Focal intestinal perforation in extremely- low-birth-weight neonates: etiological consideration from histological findings. *Pediatr Surg Int* 2007; 23: 997-1000.
 - 6) Ein SH, Marshall DG, Girvan D. Peritoneal drainage under local anesthesia for perforations from necrotizing enterocolitis. *J Pediatr Surg* 1977; 12: 963-967.
 - 7) Michel JL, Harper L, Alessandri JL, Jacquemot L, De Napoli-Cocci S, Pilorget H, Samperiz S. Peritoneal needle suction for intestinal perforation in the preterm neonate. *Eur J Pediatr Surg* 2004; 14: 85-88.
 - 8) Camberos A, Patel K, Applebaum H. Laparotomy in very small premature infants with necrotizing enterocolitis or focal intestinal perforation: postoperative outcome. *J Pediatr Surg* 2002; 37: 1692-1695.
 - 9) Cass DL, Brandt ML, Patel DL. Peritoneal drainage as definitive treatment for neonates with isolated intestinal perforation. *J Pediatr Surg* 2000; 35: 1531-1536.
 - 10) Emil S, Davis K, Ahmad I, Strauss A. Factors associated with definitive peritoneal drainage for spontaneous intestinal perforation in extremely low birth weight neonates. *Eur J Pediatr Surg* 2008; 18: 80-85.
 - 11) Rees CM, Eaton S, Kiely EM, Wade AM, McHugh K, Pierro A. Peritoneal drainage or laparotomy for neonatal bowel perforation? A randomized controlled trial. *Ann Surg* 2008; 248: 44-51.

〈和文抄録〉

初回腹腔ドレナージ術を行った超低・極低出生体重児消化管穿孔の外科治療

出口 英一, 樋口 恒司, 塚田 紫津
文野 誠久, 小野 滋, 岩田 譲司

京都第一赤十字病院小児外科

消化管穿孔を来した超低・極低出生体重児の最適な治療法は、未だ確立されていない。本報告では、地域の中核病院のNICUにおいて消化管穿孔を来した1,500 g未満の低出生体重児の治療経過を検討し、より良い手術方針を模索したい。対象と方法：2001年から2009年までに京都第一赤十字病院NICUで治療した1,500 g未満の低出生体重児の消化管穿孔5例を対象とし、後方視的に臨床研究を行った。結果：9年間に男児4例、女児1例の消化管穿孔が治療された。平均体重は834 g (534~1,042 g)で、在胎週数は26週 (23~29週)であった。消化管穿孔の診断時期は生後2から27日 (中央値6日)で、5例中4例が救命された。超低出生体重児の3例のうち2例に対しては、緊急処置として初回腹腔ドレナージ (PPD) を適応した。極低体重児2例と超低体重児1例においては、初回開腹術およびストマ造設を選択した。穿孔部位は超低体重児3例では結腸で、極低体重児2例では回腸であった。手術所見から5例中4例は壊死性腸炎で、1例はS状結腸の限局性穿孔と診断した。超低体重児3例のうち初回開腹術を行った1例を失ったが、PPDを行った2例は状態を落ち着かせた後2次開腹術を行って救命し得た。極低体重児の2例は初回開腹術により救命された。結語：今回の検討例では、超低出生体重児の消化管穿孔に対する治療としてPPDの方が初回開腹術より良好な結果につながった。

キーワード：新生児手術, 新生児消化管穿孔, 腹腔ドレナージ。